



**PATIENT PRESENTING CLINICAL SIGNS**

Oreo Parker History: Constipation past month – managed with enemas, manual evacuation, fluids, Cerenia, Miralax, and Cisapride.

**SPECIES** Physical Examination: Stricture, plaque-like lesion just proximal to the anus.

Feline Urinalysis: N/A.

**BREED** CBC: Mild anemia, neutrophilia.

DSH Serum Biochemistry: Elevated globulins, abnormal fPL.

Radiographic Findings: Spondylitis L7-S1, poor serosal detail mid-abdomen.

**SEX**

FS

**AGE**

16 years

**WEIGHT**

9.6 #

**INTERPRETED BY**

Remo Lobetti, BVSc,  
MMedVet (Med), PhD, Dipl.  
ECVIM

**ULTRASONOGRAPHIC EXAMINATION OF THE ABDOMEN**

**Urinary System**

Full urinary bladder with a normal thickness and appearance of the wall. Normal anechoic urine with no sediment or uroliths evident.

Normal trigone area, proximal urethra, and iliac blood vessels.

Normal iliac lymph nodes. Ureters not visualized.

Normal renal size (left 3.6 cm, right 3.8 cm) with increased echogenic appearance, some loss of cortico-medullary differentiation, and normal blood flow, pelvis, and capsule.

**Reproductive System**

N/A.

**Adrenal Glands**

Normal shape, echogenic appearance, size, and position. Left 0.9. x 0.39/0.23 cm, right 0.89 x 0.43/0.25 cm.

**Spleen**

Normal size and echogenic appearance. Smooth homogenous parenchyma, smooth curvi-linear capsule, and normal vasculature. No evidence of inflammatory, neoplastic, infarction, or infiltrative changes noted

**Liver**

Normal size, echogenic appearance, and portal markings. No nodules or masses evident. Full gall bladder containing normal anechoic bile. Normal thickness and echogenic appearance of the gall bladder wall. Normal bile duct.

**Gastrointestinal**

Normal appearance of the stomach, duodenum, small intestine, ileo-cecal junction, and colon with no loss of layering, normal wall and peristaltic activity, and no distension of the lumen. Fecal material within the colon.

**INVOICE**

303062

**DATE**

6/24/22

**IMAGING PERFORMED BY**

Dr Heather Brenner

**HOSPITAL NAME**

Riverside Animal Clinic

**REFERRING VET**

Dr Heather Brenner



**PATIENT** *Pancreas*

Oreo Parker Normal size with a hyperechogenic appearance. Hyperechogenic appearance of the mesentery and fat surrounding the pancreas.

**SPECIES** *Free Abdomen*

Feline No mesenteric lymphadenomegaly.  
No ascites.

**BREED**

DSH

**ULTRASONOGRAPHIC FINDINGS**

**SEX**

Primary Findings:

FS

- Pancreatic fibrosis/pancreatitis.

**AGE**

Secondary Findings:

16 years

- Age-related renal changes.

**WEIGHT**

9.6 #

**INTERPRETATION OF THE FINDINGS & FURTHER RECOMMENDATIONS**

Although the appearance of the pancreas is consistent with pancreatic fibrosis, chronic pancreatitis needs to be considered.

**INTERPRETED BY**

Remo Lobetti, BVSc,  
MMedVet (Med), PhD, Dipl.  
ECVIM

The spondylosis at L7-S1 could well be contributing to the constipation – pain and/or nerve dysfunction.

Further assessment would quantitative fPL/PSL assay, neurological examination, and possibly CT/MRI scan of the lumbar spine.

**IMAGING PERFORMED BY**

Dr Heather Brenner

Specific therapy would be dependent on an etiological diagnosis.

**HOSPITAL NAME**

Riverside Animal Clinic

**REFERRING VET**

Dr Heather Brenner

**INVOICE**

303062

**DATE**

6/24/22



**PATIENT IMAGES**

Oreo Parker **Pancreas**

**SPECIES**

Feline

**BREED**

DSH

**SEX**

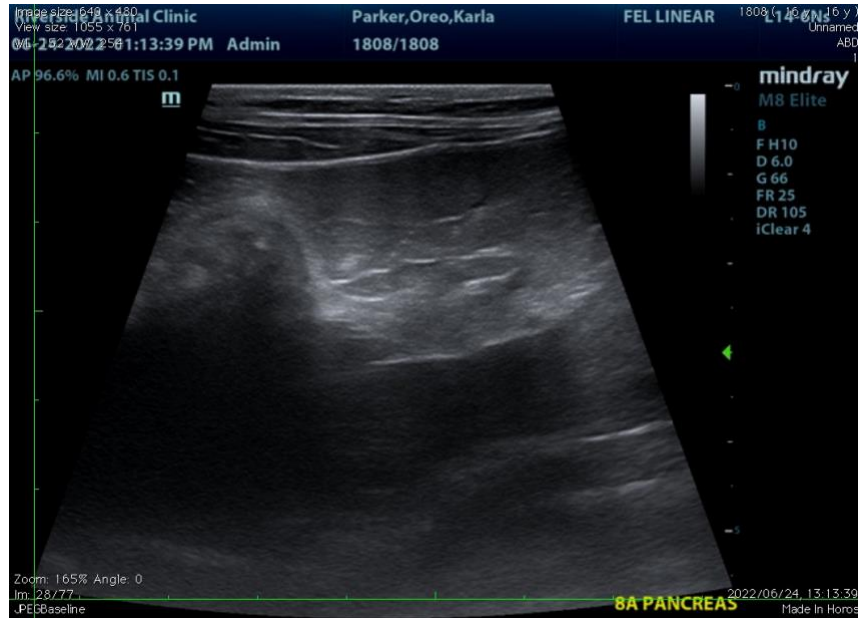
FS

**AGE**

16 years

**WEIGHT**

9.6 #



**INTERPRETED BY**

Remo Lobetti, BVSc,  
MMedVet (Med), PhD, Dipl.  
ECVIM

**The information and recommendations provided are based on the images presented by the referring veterinarian. No evaluation can be communicated regarding pathology that was not visible in the image/video clips provided.**

Thank you for this referral. If the clinical or image interpretation does not parallel your findings or if I can be of any further assistance, please contact me.

**Remo Lobetti, BVSc, MMedVet (Med), PhD, Dipl. ECVIM (Internal Medicine)**  
[rlobetti@mweb.co.za](mailto:rlobetti@mweb.co.za)

**IMAGING PERFORMED BY**

Dr Heather Brenner

**HOSPITAL NAME**

Riverside Animal Clinic

**REFERRING VET**

Dr Heather Brenner

**INVOICE**

303062

**DATE**

6/24/22